



Scholars Research Library

Der Pharmacia Lettre, 2015, 7 (12):285-295
(<http://scholarsresearchlibrary.com/archive.html>)



New approach on the horizon in retraction of liver cancer using selenium nanoparticles

Amal H. Hamza^{1,2}, Mohamed Diao Abd El-Maksoud³, Nevein N. Fadl⁴
and Hanaa H. Ahmed^{5*}

¹Biochemistry Department, Faculty of Science-AlFaisalia Campus, King Abdulaziz University, Jeddah, KSA

²Biochemistry and Nutrition Department, Faculty of Women for Arts, Science and Education, Ain Shams University, Cairo, Egypt

³Biochemistry Department, National Research Centre, Dokki, Giza, Egypt (Affiliation ID 60014618)

⁴Medical Physiology Department, National Research Centre, Dokki, Giza, Egypt (Affiliation ID 60014618)

⁵Hormones Department, National Research Centre, Dokki, Giza, Egypt (Affiliation ID 60014618)

ABSTRACT

Selenium (Se) nanoparticle is a novel Se species with a unique biological activity and low toxicity. This experiment was constructed to explore new approach in recession of hepatocellular carcinoma using selenium nanoparticles. Biochemical and immunohistochemical markers were conducted to prove our hypothesis. Seventy adult male albino rats were randomly assigned into seven groups. Negative control, Nano-Se, HCC, HCC + Doxo, HCC + Nano-Se (therapeutic), HCC + Nano-Se (protection), HCC + Doxo + Nano-Se. The biochemical results revealed significant ameliorative effect of Nano-Se administration on liver enzymes (ALT, AST and ALP) in serum. Circulating level of α -fucosidase and α -fetoprotein and carcinoembryonic antigen were significantly depleted upon administration of Nano-Se. Regarding immunohistochemical findings, the expression of β -catenin, survivin and Ki-67 was down-regulated as a result of Nano-Se administration prior or post induction of HCC. The present study sheds light on the potent role of Nano-Se in retrogression of hepatocellular carcinoma in the experimental model. This study represented a new modality in the treatment of HCC using the aspect of nanotechnology.

Keywords: Selenium nanoparticle, hepatocellular carcinoma, tumor markers, apoptosis, proliferation, rats.

INTRODUCTION

The trace element selenium, an essential element for animals and humans, has been shown to affect the functions of several specific intracellular selenoproteins by being a component of their essential constituent selenocysteine. It was first suggested in the late 1960s that Se might be anticarcinogenic, based on an inverse relationship of Se status and risks of some kinds of cancer. Since then, a substantial body of evidence indicates that Se can indeed play a role in cancer prevention [1].

It is well known that selenium has a narrow margin between beneficial and toxic effects. As a promising chemopreventive agent, its use requires consumption over the long term, so the toxicity of Se is always a crucial concern [2]. Nanotechnology gives a new hope for medication and nutrition because materials at the nanometer dimension exhibit novel properties different to those of both isolated atoms and bulk material. In this regard, it has

been suggested by Zhang *et al.* [3] that Nano-Se can serve as a potential chemopreventive agent with reduced risk of Se toxicity.

Accumulating evidences have led to several mechanisms being proposed for the anticancer activity of Se. These include antioxidant defense mechanism, alteration of carcinogen metabolism, enhancement of immune surveillance, regulation of cell proliferation and tumor cell invasion as well as inhibition of neoangiogenesis [4].

Cancer of the liver is the fifth most common cancer in the world. The incidence of liver cancer varies widely throughout the world, with high rates in sub-Saharan Africa, eastern and southeastern Asia, and Melanesia and low incidence in Northern and Western Europe and the Americas. The incidence among men is over twice that among women [5].

Primary cancers of the liver in adults are of two main histological types: hepatocellular carcinoma (HCC), which is derived from hepatocytes, and cholangiocarcinoma, which is derived from the epithelial lining of the intrahepatic bile ducts. Among primary liver cancers, HCC is the most common type occurring worldwide. The nomenclature of this subtype was revised by WHO [6, 7]. Hepatocellular carcinoma is a frequently occurring tumor in individuals in many developing countries, where several important risk factors have been demonstrated, including chronic infection with hepatitis B and C viruses and other environmental factors, such as exposure to aflatoxin, consumption of alcohol, and cigarette smoking [5].

The present research study goaled to explore the role of Nano-Se in regression of hepatocellular carcinoma in chemically induced animal model.

MATERIALS AND METHODS

a. Preparation of nano-selenium (Nano-Se)

Nano-selenium was prepared by a simple wet chemical method according to Dwivedi *et al.* [8]. Briefly, sodium selenosulphate precursor was reacted with different organic acids in aqueous medium, under ambient conditions. Polyvinyl alcohol has been used to stabilize the selenium nanoparticles. Then, the synthesized nanoparticles (Nano-Se) 50 - 90 nm in size (**Fig. 1**) were separated from their sol by using a high-speed centrifuge and redispersed in aqueous medium with a sonicator.




Fig. (1): High-resolution transmission electron microscopy image of Nano-Se

b. Characterization of Nano-Se

The synthesized Nano-Se was characterized by JEOL JEM-2100 high resolution transmission electron microscope (TEM) at an accelerating voltage of 200 kV. TEM samples were prepared by suspending the obtained nanoparticles in phosphate buffer and applying one drop of this suspension on copper grids coated by thin film of carbon.

c. Animals

Seventy adult male albino rats (140±10g) obtained from the Animal House Colony of National Research Centre, Giza, Egypt, were enrolled in the present study. The animals were housed in transparent plastic cage with wood shavings at a freely ventilated and naturally illuminated room with controlled temperature (25±5°C) and humidity (50±10%). Animals were fed with standard laboratory rat diet consisting of casein 10%, salts mixture 4 %, vitamins mixture 1%, corn oil 10 % and cellulose 5% completed to 100 g with corn starch [9] and water provided *ad libitum*. Animals were allowed to adapt to their environment for at least 10 days before the initiation of the experiment.

The experimental protocol complied with the guidelines for animals experiment which were approved by the Ethical Committee of the Medical Research of the National Research Centre.

d. Experimental design

After the acclimatization period, the rats were randomly assigned into seven groups (10 rats each). **Group (1)** Healthy group set as negative control received 0.5 ml saline daily during the experimental period. **Group (2)** Healthy group treated with Nano-Se (5mg/kg b.wt., 3 times/week for 3 weeks) according to Zhang et al. [2] (Nano-Se). **Group (3)** Healthy group orally administered with N-nitrosodiethylamine (NDEA) at a dose of 20 mg/kg b.wt. five times a week during a period of 4 weeks, then 10 mg/kg b.wt. for another week [10] and set as HCC group (HCC). **Group (4)** HCC bearing group treated with doxorubicin in a dose of 0.072 mg/rat which is equivalent to the human dose 20 mg/m² according to Barnes and Paget [11] once weekly for 3 weeks (HCC + DOXO). **Group (5)** HCC bearing group treated with Nano-Se (5 mg/kg b.wt., 3 times/week) for 3 weeks (HCC + Nano-Se therapeutic). **Group (6)** Healthy group treated with Nano-Se (5 mg/kg b.wt., 3 times/week) for 3 weeks then orally administered with NDEA for a period of 5 weeks for induction of HCC (HCC + Nano-Se protection). **Group (7)** HCC bearing group treated with Nano-Se (5 mg/kg b.wt., 3 times/week) and doxorubicin (0.072 mg/rat once weekly) for 3 weeks (HCC + Nano-Se + DOXO).

At the end of the experimental period, rats were fasted overnight and subjected to diethylether anesthesia. The blood samples were immediately withdrawn from the retro-orbital venous plexus and stored at -20°C pending further analysis. Then, the rats were sacrificed by cervical dislocation and the liver specimens were excised, rinsed with saline solution and fixed in formalin saline (10%) for immunohistochemical examination.

e. Biochemical analyses

Routine liver function tests (ALT and AST) were assayed according to Reitman and Frankel [12] and serum ALP was estimated following the method described by Belfield and Goldberg [13]. Serum α -fucosidase (AFU) and α -fetoprotein (AFP) were determined by enzyme linked immunosorbent assay (ELISA) according to the manufacture instructions of Glory Science Co., assay kit, TX (USA). Serum carcinoembryonic antigen (CEA) was detected by ELISA using CEA assay kit according to the method of Schwartz [14].

f. Immunohistochemical examination

The fixed liver tissues were washed in tap water, and then serial dilutions of alcohol (methyl, ethyl and absolute ethyl) were used for dehydration. Liver specimens were cleared in xylene and embedded in paraffin at 56°C in hot air oven for 24 h. Paraffin bees wax tissue blocks were prepared for sectioning transversely at 4 μ m by sledge microtome. Sections were fixed in 65°C oven for 1h. Rabbit polyclonal primary antibody for β -catenin (Thermoscientific, CA-USA, Cat# RB-9041-R7), survivin (Thermoscientific, CA-USA, Cat# RB-9245-R7) and Ki-67 (Lab Vision Co., Fremont, California, USA, Cat# RB-9043-R7) were used in immunohistochemical assay. Henceforward, poly horseradish peroxidase (HRP) enzyme conjugate was applied to each slide for 20 min. 3,3' Diaminobenzidine (DAB) chromogen was prepared and 2 to 3 drops were applied on each slide for 2 min. DAB was washed, rinsed, after which counterstaining with Mayer hematoxylin and cover slipping were performed as the final steps before slides were examined under the light microscope. Image J software (NIH, version v1.45e, USA) was calibrated and the image is opened on the computer screen for image analysis.

Statistical analysis

Data of the present study were expressed as mean \pm standard error (SE) of the mean. Data were analyzed by one way analysis of variance (ANOVA) using the Statistical Package for the Social Sciences (SPSS) program, version 11. Difference was considered significant when P value was <0.05 .

RESULTS**Biochemical results****a- Liver enzymes analysis**

The data illustrated in **Table (1)** show the therapeutic and protective potential of Nano-Se on serum activity of liver enzymes in HCC rat model. In comparison with the negative control group, there was significant increase ($p<0.05$) in serum ALT, AST and ALP activity in HCC group. Either post-treatment or pre-treatment of HCC group with Nano-Se elicited a significant decrease ($p<0.05$) in serum ALT, AST and ALP activity as compared to the untreated HCC group. Interestingly, there was significant depletion ($p<0.05$) in serum ALT, AST and ALP activity in both Nano-Se-treated and Nano-Se-protected groups in comparison with doxorubicin-treated group.

Table (1): Therapeutic and protective effect of Nano-Se on liver functions in the different experimental groups

Groups	ALT (U/L)	AST (U/L)	ALP (U/L)
Negative control	26.7 \pm 0.5	42.8 \pm 0.6	143.2 \pm 2.7
Nano-Se	28.7 \pm 1.7	46.9 \pm 1.1	145.0 \pm 3.4
HCC	52.7 \pm 0.7 ^a	80.3 \pm 1.5 ^a	281.8 \pm 5.1 ^a
HCC + DOXO	50.1 \pm 2.0	78.6 \pm 1.6	274.8 \pm 4.7
HCC + Nano-Se (therapeutic)	37.9 \pm 2.5 ^{bc}	56.6 \pm 1.7 ^{bc}	152.0 \pm 1.8 ^{bc}
HCC + Nano-Se (protective)	45.8 \pm 0.8 ^{bc}	58.2 \pm 2.3 ^{bc}	165.2 \pm 2.1 ^{bc}
HCC + Nano-Se + DOXO	50.8 \pm 0.5	78.9 \pm 0.8	279.6 \pm 2.7

Data are expressed as means \pm standard error (SE)

a: Significance change at $P < 0.05$ in comparison with the negative control group.

b: Significance change at $P < 0.05$ in comparison with HCC group.

c: Significance change at $P < 0.05$ in comparison with DOXO-treated group.

b- Tumor markers analysis

The data presented in **Table (2)** reveal the therapeutic and protective effect of Nano-Se on tumor markers serum levels in HCC rat model. The present results demonstrated that there was significant elevation ($p<0.05$) in serum levels of AFU, AFP and CEA in HCC group when compared with the negative control group. Post-treatment or pre-treatment of HCC group with Nano-Se caused significant depletion ($p<0.05$) in AFU, AFP and CEA serum levels as compared to the untreated HCC group. Similarly, treatment of HCC group with doxorubicin experienced significant decrease ($p<0.05$) in serum levels of AFU, AFP and CEA as compared to the untreated HCC group. Of note, HCC groups post-treated or pre-treated with Nano-Se showed significant decrease ($p<0.05$) in serum level of AFP in comparison with the group treated with doxorubicin. Regarding CEA, post-treatment of HCC group with Nano-Se caused significant decrease ($p<0.05$) in CEA serum level, relative to the group treated with doxorubicin. On the other hand, treatment of HCC group with Nano-Se in combination with doxorubicin elicited significant increase ($p<0.05$) in serum levels of AFU and CEA versus the group treated with doxorubicin.

Table (2): Therapeutic and protective effect of Nano-Se on tumor markers serum levels in the different experimental groups

Groups	α -Fucosidase (pg/ml)	α -Fetoprotein (ng/ml)	CEA (ng/ml)
Negative control	55.8 \pm 2.4	23.7 \pm 0.8	0.12 \pm 0.01
Nano-Se	52.2 \pm 1.2	20.9 \pm 1.3	0.14 \pm 0.01
HCC	90.7 \pm 4.9 ^a	41.9 \pm 1.7 ^a	0.72 \pm 0.05 ^a
HCC + DOXO	80.5 \pm 1.9 ^b	36.0 \pm 1.7 ^b	0.58 \pm 0.05 ^b
HCC + Nano-Se (therapeutic)	74.0 \pm 1.5 ^b	29.1 \pm 1.0 ^{bc}	0.37 \pm 0.03 ^{bc}
HCC + Nano-Se (protective)	78.4 \pm 1.7 ^b	30.6 \pm 1.8 ^{bc}	0.53 \pm 0.02 ^b
HCC + Nano-Se + DOXO	88.1 \pm 0.9 ^c	39.7 \pm 0.8	0.68 \pm 0.02 ^c

Data are expressed as means \pm standard error (SE)

a: Significance change at $P < 0.05$ in comparison with the negative control group.

b: Significance change at $P < 0.05$ in comparison with HCC group.

c: Significance change at $P < 0.05$ in comparison with DOXO-treated group.

Immunohistochemical results

The expression of β -catenin, survivin and Ki-67 in the liver tissue of rats in the different experimental groups were

investigated by immunohistochemical assay.

a- β -catenin expression

Representative photomicrographs of β -catenin immunohistochemical staining are illustrated in **Figs [2a-g]**. Immunohistochemical staining of liver tissue section of rat in the negative control group using antibody against β -catenin showed negative reaction in the nuclei of liver cells (**Fig. 2a**). Photomicrograph for immunohistochemical staining of liver tissue section of rat treated with Nano-Se alone showed slight positive reaction for β -catenin in the nuclei of liver cells (**Fig. 2b**). Meanwhile, photomicrograph for immunohistochemical staining of liver tissue section of rat in HCC group showed severe positive reaction for β -catenin in the nuclei of liver cells (**Fig. 2c**). Photomicrograph for immunohistochemical staining of liver tissue section of rat in HCC group treated with doxorubicin showed mild positive reaction for β -catenin in the nuclei of liver cells (**Fig. 2d**). Photomicrograph for immunohistochemical staining of liver tissue section of rat in HCC group post-treated with Nano-Se showed negative reaction for β -catenin in the nuclei of liver cells (**Fig. 2e**). Photomicrograph for immunohistochemical staining of liver tissue section of rat in HCC group pre-treated with Nano-Se showed faint positive reaction for β -catenin in the nuclei of liver cells (**Fig. 2f**). Photomicrograph for immunohistochemical staining of liver tissue section of rat in HCC group treated with Nano-Se and doxorubicin showed moderate positive reaction for β -catenin in the nuclei of liver cells (**Fig. 2g**).

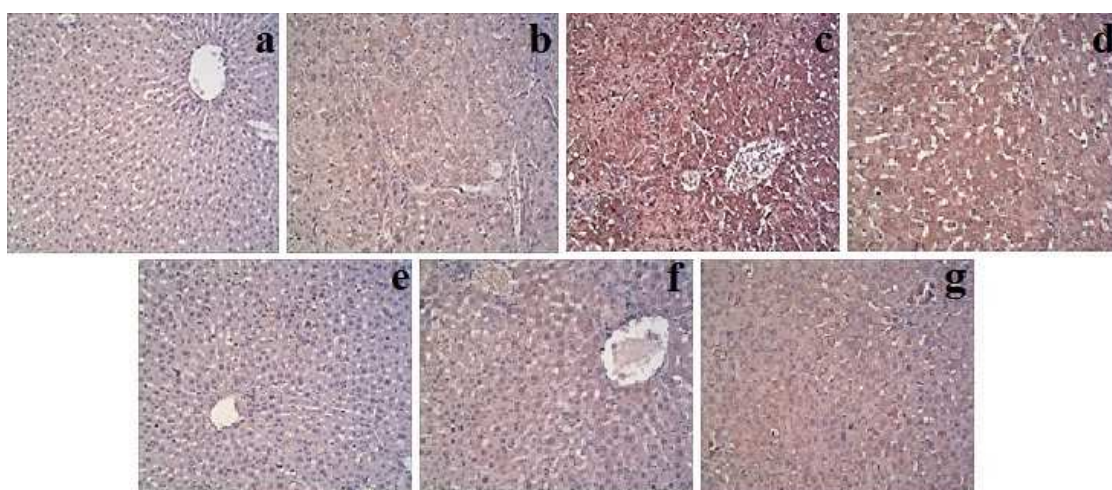


Fig. [2] Immunohistochemical results for β -catenin expression in liver tissue of rats in the different experimental groups

- Fig. (2a): Photomicrograph for immunohistochemical staining of liver tissue section of rat in the negative control group rats using antibody against β -catenin showed negative reaction in the nuclei of liver cells (100x).
- Fig. (2b): Photomicrograph for immunohistochemical staining of liver tissue section of rat treated with Nano-Se alone using antibody against β -catenin showed slight positive reaction in the nuclei of liver cells (100x).
- Fig. (2c): Photomicrograph for immunohistochemical staining of liver tissue section of rat in HCC group using antibody against β -catenin showed severe positive reaction in the nuclei of liver cells (100x).
- Fig. (2d): Photomicrograph for immunohistochemical staining of liver tissue section of rat in HCC group treated with doxorubicin using antibody against β -catenin showed mild positive reaction in the nuclei of liver cells (100x).
- Fig. (2e): Photomicrograph for immunohistochemical staining of liver tissue section of rat in HCC group post-treated with Nano-Se using antibody against β -catenin showed negative reaction in the nuclei of liver cells (100x).
- Fig. (2f): Photomicrograph for immunohistochemical staining of liver tissue section of rat in HCC group pre-treated with Nano-Se using antibody against β -catenin showed faint positive reaction in the nuclei of liver cells (100x).
- Fig. (2g): Photomicrograph for immunohistochemical staining of liver tissue section of rat in HCC group treated with Nano-Se and doxorubicin using antibody against β -catenin showed moderate positive reaction in the nuclei of liver cells (100x).

b- Survivin expression

Representative photomicrographs of survivin immunohistochemical staining are depicted in the **Figs [3a-g]**. Immunohistochemical staining of liver tissue section of rat in the negative control group using antibody against survivin showed negative reaction in the nuclei of liver cells (**Fig. 3a**). Photomicrograph for immunohistochemical staining of liver tissue section of rat treated with Nano-Se alone showed slight positive reaction for survivin in the nuclei of liver cells (**Fig. 3b**). However, photomicrograph for immunohistochemical staining of liver tissue section of rat in HCC group showed severe positive reaction for survivin in the nuclei of liver cells (**Fig. 3c**). Photomicrograph for immunohistochemical staining of liver tissue section of rat in HCC group treated with

doxorubicin showed mild positive reaction for survivin in the nuclei of liver cells (**Fig. 3d**). Photomicrograph for immunohistochemical staining of liver tissue section of rat in HCC group post treated with Nano-Se showed faint positive reaction for survivin in the nuclei of liver cells (**Fig. 3e**). Photomicrograph for immunohistochemical staining of liver tissue section of rat in HCC group pre-treated with Nano-Se showed mild positive reaction for survivin in the nuclei of liver cells (**Fig. 3f**). Photomicrograph for the immunohistochemical staining of liver tissue section of rat in HCC group treated with Nano-Se and doxorubicin showed moderate positive reaction for survivin in the nuclei of liver cells (**Fig. 3g**).

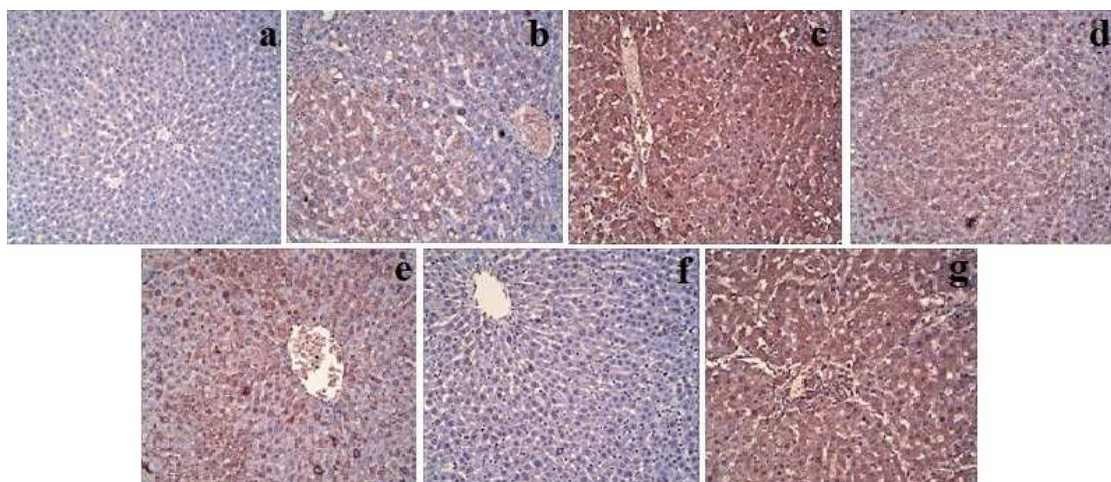


Fig. [3] Immunohistochemical results for survivin expression in liver tissue of rats in the different experimental groups.

Fig. (3a): Photomicrograph for immunohistochemical staining of liver tissue section of rat in the negative control group using antibody against survivin showed negative reaction in the nuclei of liver cells (100x).

Fig. (3b): Photomicrograph for immunohistochemical staining of liver tissue section of rat treated with Nano-Se alone using antibody against survivin showed slight positive reaction in the nuclei of liver cells (100x).

Fig. (3c): Photomicrograph for immunohistochemical staining of liver tissue section of rat in HCC group using antibody against survivin showed severe positive reaction in the nuclei of liver cells (100x).

Fig. (3d): Photomicrograph for immunohistochemical staining of liver tissue section of rat in HCC group treated with doxorubicin using antibody against survivin showed mild positive reaction in the nuclei of liver cells (100x).

Fig. (3e): Photomicrograph for immunohistochemical staining of liver tissue section of rat in HCC group post-treated with Nano-Se using antibody against survivin showed faint positive reaction in the nuclei of liver cells (100x).

Fig. (3f): Photomicrograph for immunohistochemical staining of liver tissue section of rat in HCC group pre-treated with Nano-Se using antibody against survivin showed mild positive reaction in the nuclei of liver cells (100x).

Fig. (3g): Photomicrograph for immunohistochemical staining of liver tissue section of rat in HCC group treated with Nano-Se and doxorubicin using antibody against survivin showed moderate positive reaction in the nuclei of liver cells (100x).

c- Ki-67 expression

Photomicrographs of Ki-67 immunohistochemical staining are represented in **Figs [4a-g]**. Photomicrograph for immunohistochemical staining of liver tissue section of rat in the negative control group using antibody against Ki-67 showed negative reaction in the nuclei of liver cells (**Fig. 4a**). Similarly, photomicrograph for immunohistochemical staining of liver tissue section of rat treated with Nano-Se alone showed negative reaction for survivin in the nuclei of liver cells (**Fig. 4b**). Whereas, photomicrograph for immunohistochemical staining of liver tissue section of rat in HCC group showed very severe positive reaction for Ki-67 in the nuclei of liver cells (**Fig. 4c**). Photomicrograph for immunohistochemical staining of liver tissue section of rat in HCC group treated with doxorubicin showed mild positive reaction for Ki-67 in the nuclei of liver cells (**Fig. 4d**). Photomicrograph for immunohistochemical staining of liver tissue section of rat in HCC group post-treated with Nano-Se showed mild positive reaction for Ki-67 in the nuclei of liver cells (**Fig. 4e**). Photomicrograph for immunohistochemical staining of liver tissue section of rat in HCC group pre-treated with Nano-Se showed moderate positive reaction for Ki-67 in the nuclei of liver cells (**Fig. 4f**). Photomicrograph for immunohistochemical staining of liver tissue section of rat in HCC group treated with Nano-Se and doxorubicin showed severe positive reaction for Ki-67 in the nuclei of liver cells (**Fig. 4g**).

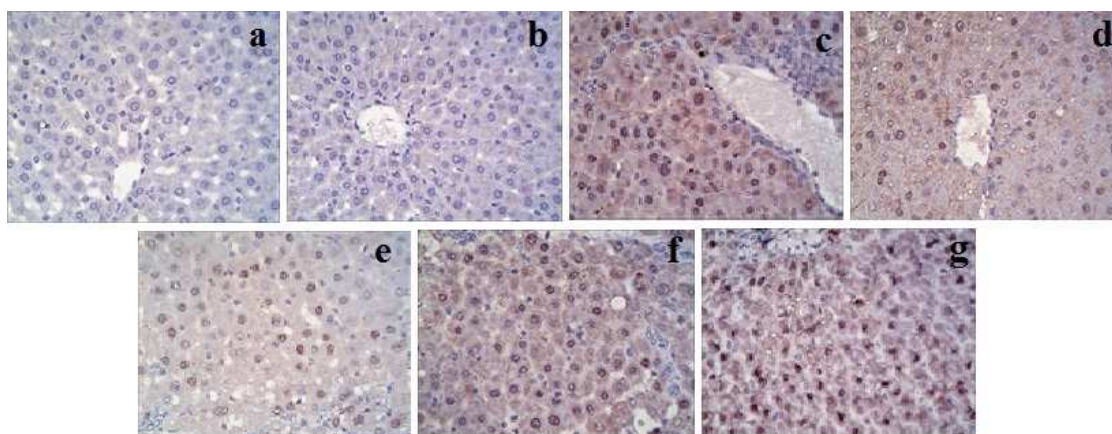


Fig. [4] Immunohistochemical results for Ki-67 expression in liver tissue of rats in the different experimental groups

- Fig. (4a): Photomicrograph for immunohistochemical staining of liver tissue section of rat in the negative control group using antibody against Ki-67 showed negative reaction in the nuclei of liver cells (100x).
- Fig. (4b): Photomicrograph for immunohistochemical staining of liver tissue section of rat treated with Nano-Se alone using antibody against Ki-67 showed negative reaction in the nuclei of liver cells (100x).
- Fig. (4c): Photomicrograph for immunohistochemical staining of liver tissue section of rat in HCC group using antibody against Ki-67 showed very severe positive reaction in the nuclei of liver cells (100x).
- Fig. (4d): Photomicrograph for immunohistochemical staining of liver tissue section of rat in HCC group treated with doxorubicin using antibody against Ki-67 showed mild positive reaction in the nuclei of liver cells (100x).
- Fig. (4e): Photomicrograph for immunohistochemical staining of liver tissue section of rat in HCC group post-treated with Nano-Se using antibody against Ki-67 showed mild positive reaction in the nuclei of liver cells (100x).
- Fig. (4f): Photomicrograph for immunohistochemical staining of liver tissue section of rat in HCC group pre-treated with Nano-Se using antibody against Ki-67 showed moderate positive reaction in the nuclei of liver cells (100x).
- Fig. (4g): Photomicrograph for immunohistochemical staining of liver tissue section of rat in HCC group treated with Nano-Se and doxorubicin using antibody against Ki-67 showed severe positive reaction in the nuclei of liver cells (100x).

DISCUSSION

Hepatocellular carcinoma is one of the most fatal malignancies, with a 5-year survival rate of 10 % or less. Conventional chemo and radio-therapy play an important role in the treatment of hepatocellular carcinoma, but clinical limitations exist because of dose-limiting side effects and drug resistance, this reiterates the need for alternative therapies with more efficacy [15]. Therefore, the present work was designed to explore the efficacy of Nano-Se in suppressing hepatocellular carcinoma in rat model. The results of the current study revealed that the administration of the carcinogenic agent (NDEA) in rats significantly increased the activity of liver enzymes (AST, ALT and ALP) in serum. The amount of these cellular enzymes present in the blood reflects the alteration in plasma membrane integrity and/or permeability. These findings are in conformity with those of Willimsky *et al.* [16]. The mechanism underlying this effect seems to be attributed to the free radicals production during NDEA metabolism, which induce oxidative damage of the hepatic cell membrane. As a result, these cytoplasmic enzymes, normally located in the cytosol, leaked into the circulation from the hepatocytes resulting in the increased activity of such enzymes in serum [17].

The present results revealed that the treatment of HCC group with doxorubicin caused insignificant change in serum ALT, AST and ALP enzymes activity relative to the untreated HCC group. Doxorubicin has a metabolic activity that elicits generation of free radicals and induction of oxidative stress leading to liver tissue injury [18]. Hence, doxorubicin causes an imbalance between free oxygen radicals (ROS) and antioxidants enzymes resulting in liver damage [19], as indicated by the increased serum indices of liver functions including ALT, AST and ALP. The elevated serum activity of liver enzymes as indicators, for hepatocellular damage has been previously reported in doxorubicin-induced hepatotoxicity model [20].

The present study showed that the administration of HCC group with Nano-Se resulted in significant decrease in serum AST, ALT and ALP activity as compared with those in the untreated HCC group. The depletion in serum enzyme activity indicates the ability of Nano-Se to maintain the normal structural and architectural organization of hepatocytes by restricting the leakage of these enzymes which can be accounted for membrane-stabilizing property of Nano-Se. This explanation comes in line with that of Ahmed *et al.* [21] who proved the adequacy of selenium to

preserve the structural integrity of hepatocellular membrane and restore hepatic functions in rats with liver fibrosis induced by thioacetamide. This finding is also in harmony with that of Kumar et al. [22] who reported a significant reduction in the activity of liver enzymes (AST, ALT and ALP) in serum of rats with hepatic damage and treated with selenium. Moreover, Ozardali et al. [23] stated that selenium could diminish the hepatotoxic effect of CCl_4 -metabolites through its antioxidant activity which is responsible for the modulation of hepatic cellular injury and improvement of liver functions.

In view of the present data, serum AFU activity was found to be significantly increased in rats bearing HCC as a consequence of NDEA administration. This result is in consonance with the study of Chen et al. [24]. Although the mechanism by which AFU increases in HCC is still unknown, but the possible mechanism for that increase may be attributed to the increased synthesis of proteins by tumor due to the exponential growth of malignant cells with a consequent increase in fucose turnover [25].

The present findings demonstrated significant augmentation in the serum level of AFP in HCC group induced by NDEA administration. This finding is in accordance with that of Song et al. [26]. AFP is a fetal glycoprotein produced mainly by the fetal liver. Normally, its serum level declines rapidly after birth and its synthesis is suppressed in adults [27]. The possible explanation for the reinitiation of AFP synthesis by neoplastic hepatocytes may be due to the increased activity of nuclear factor kappa B (NF- κ B) which is known to be implicated in HCC [28]. NF- κ B is an inducible transcription factor that regulates the expression of genes involved in inflammation, cellular proliferation, cell survival and carcinogenesis [29]. Previous study of Cui et al. [30] suggested that the inflammation is the main cause of AFP production.

In this study, serum CEA level in the group with HCC induced by NDEA administration showed significant elevation. Such increase in serum CEA level was presumably associated with the progression rate of tumor, its location, stage, size, differentiation and vascularity [31]. Macnab et al. [32] demonstrated that the tumor could induce a release of CEA from the damaged liver cells adjacent to it. Another earlier study reported that CEA is normally cleared from the circulating plasma by the liver [33]. Thus, the increased serum levels of CEA could be resulted from the impaired hepatic uptake of CEA or CEA-like glycoproteins.

The present finding revealed that Nano-Se administration post or pre induction of HCC resulted in significant depletion in the activity of AFU in serum. The antitumor activity of selenium has been previously reported by Jiang et al. [34]. The capability of selenium to inhibit tumor growth accounts for the reduction of protein synthesis by tumor cells with consequent decrease of fucose turnover and AFU production.

The current study recorded that AFP serum level in Nano-Se administrated groups (after or before induction of cancer) was significantly reduced. This result is in keeping with that of Liu et al. [35]. These authors suggested that selenium might deaden the lesion of the liver and delay NDEA-induced hepatocarcinogenesis in rats. This results in decreased AFP production with consequent reduction of its serum level. This indicates the antitumor effect and antiangiogenic activity of selenium which lead to the decreasing of tumor growth with observed depletion in AFP synthesis by tumor cells.

The present results indicated that administration of Nano-Se after or before induction of HCC significantly reduced CEA serum level. This result is supported by the result observed by Hamdy et al. [36]. The observed depletion in CEA serum level by Nano-Se may be attributed to its anticancer potential which results in tumor volume reduction and inhibition of protein synthesis by the malignant cells. This suggestion comes in line with the study of Bhattacharya et al. [37] which demonstrates that selenium possesses anticancer and antiangiogenic efficacy that results in a significant inhibition of tumor growth in an orthotopic model of human colon cancer. Moreover, other earlier study showed that the chemoprotective effect of selenium was due to its inhibitory effect on cell growth, and protein synthesis in transformed cell [38].

The current data revealed that the treatment with doxorubicin in HCC bearing rats resulted in significant decrease in AFU, AFP and CEA serum levels. Moustafa et al. [39] stated that the treatment of HCC patients with three intravenous cycles of adriamycin decreased AFP serum level. The possible explanation for the observed depletion in AFP, AFU and CEA serum levels by doxorubicin may be due to its ability to reduce the tumor mass resulting in decreased protein synthesis by the tumor. This suggestion is in agreement with that of Kusuzaki et al. [40] who reported that doxorubicin treatment resulted in decreasing the volume of malignant soft tissue tumors.

The results of the current study revealed that there was marked upregulation of the expression of β -catenin in the liver tissue of HCC group. HCC is a multifactorial disease resulted from the dysregulation of multiple pathways. One of the most significant pathways in HCC is the Wnt/ β -catenin signaling. β -catenin is the central effector of the canonical Wnt signaling, the major regulator of many cellular processes such as proliferation, differentiation, survival and self-renewal [41]. Suzuki et al. [42] found that β -catenin protein expression was located mainly in the cell membrane of highly differentiated HCC tissue with a low Ki-67 proliferation index. While, cytoplasmic or nuclear β -catenin protein expression was observed in less differentiated HCC tissue with a high proliferation index. Thus, it can be hypothesized that, to some extent, the change in localization of β -catenin expression reflects the differentiation of HCC tissues.

In view of the present data, remarkable overexpression of liver survivin was observed in HCC group. This result is in conformity with that of Zhu et al. [43]. Survivin is a novel member of the inhibitors of apoptosis proteins (IAP) family that inhibits the activation of caspase-3 and -7 in cells exposed to apoptotic stimuli [44]. Many cancer cell lines, including human hepatoma cells, displayed a resistance toward TNF-related apoptosis-inducing ligand (TRAIL)-mediated apoptosis [45]. There is a growing body of evidence indicates that intracellular antiapoptotic pathways including NF- κ B and Akt modulate the response to TRAIL in many cancer cells and contribute to resistance toward TRAIL [46]. NF- κ B has been found to be upregulate the antiapoptotic molecules including survivin [47].

The current study showed detectable upregulation of Ki-67 in the liver tissue of rats bearing HCC. Umemura et al. [48] reported that high dose of NDEA administration in the experimental animals induced cell proliferation associated with DNA mutations and induction of HCC. Our finding comes in line with the study of Pizem et al. [49] which showed that Ki-67 gene expression levels were higher in neoplastic liver than in non-neoplastic one. Moreover, Ogunwobi and Liu [50] recorded significant upregulation of cyclooxygenase 2 (Cox-2) gene expression level in HCC. Cox-2 deletion has been found to significantly inhibit Ki-67 expression in the HCC xenografts. This indicates that overexpression of Cox-2 gene enhances the expression of Ki-67 [30].

The current results indicated that the administration of Nano-Se post or pre induction of HCC markedly reduced the expression of β -catenin in the liver tissue. This result is in accordance with the study performed by Luo et al. [51] which indicated that methylseleninic acid (MSA) could reduce the protein level of β -catenin and accelerate its degradation in esophageal squamous cell carcinoma. The degradation of β -catenin by MSA was probably mediated by activation of glycogen synthase kinase 3 β (GSK-3 β) activity which is a key component of β -catenin destruction complex that phosphorylates β -catenin and presents the protein for degradation by ubiquitin-proteasome system.

The current study showed that the administration of Nano-Se post or pre induction of HCC markedly reduced the expression of survivin in the liver tissue. This result is in agreement with the study of Chun et al. [52] which showed that methylseleninic acid treatment in human esophageal squamous carcinoma cell line resulted in downregulation of survivin gene. Moreover, Fang et al. [53] found that sodium selenite inhibited intestinal carcinogenesis *in vivo* and *in vitro* through activation of JNK1 and suppression of β -catenin signaling pathway resulting in downregulation of its target genes. One of the target genes of β -catenin/TCF (T cell factor) pathway which play vital roles in cell apoptosis and cell cycle regulation is survivin [54].

Nano-Se administration post or pre induction of HCC in the present work has been shown to remarkably suppress the expression of Ki-67 in the liver tissue. This result is in harmony with that of Hu et al. [55] which showed that dietary selenium intake resulted in significant inhibition of colonic epithelial proliferation through significant reduction of Ki-67 labeling index in colonic crypts. Such decrement may be due to the inhibitory effect of selenium on Cox-2 gene expression with consequent inhibition of Ki-67 expression. In line with this finding Baines et al. [56] reported that selenomethionine suppressed Cox-2 mRNA levels in HCA-7 cells (human colon cancer cell lines) which could account for decreased Cox-2 protein levels. Thus, the decrease in Cox-2 gene expression level may be attributed to the observed decrease in Ki-67 expression in the liver tissue of rats administered Nano-Se as shown in the present study. Interestingly, Luo et al. [57] found that HeLa (human cervical carcinoma) cells treated with Nano-Se were arrested in the S phase. When cancer cells are arrested in the S phase, the mitosis and proliferation of cancer cells are inhibited. Thus, Nano-Se could significantly inhibit the proliferation rate of HeLa cells, with consequent down regulation of the proliferative markers including Ki-67.

The present study demonstrated that doxorubicin treatment in HCC bearing rats elicited remarkable downregulation in β -catenin, survivin and Ki-67 expression in the liver tissue. These findings might be attributed to the apoptotic and antiproliferative effects exerted by doxorubicin [58]. There are two proposed mechanisms by which doxorubicin could act in cancer cells, (i) intercalation into DNA and disruption of topoisomerase-II-mediated DNA repair and (ii) generation of free radicals with their damaging impact on cellular membranes, DNA and proteins [59]. Also, the apoptotic effect of doxorubicin is correlated with the redox activation of doxorubicin by endothelial nitric oxide synthase (eNOS) [60]. Denard et al. [61] reported that doxorubicin inhibited proliferation through stimulating *de novo* synthesis of ceramide, which in turn activates CREB3L1, a transcription factor synthesized as a membrane bound precursor. Doxorubicin stimulated proteolytic cleavage of CREB3L1 by site-1 protease and site-2 protease, allowing the NH₂ terminal domain to enter the nucleus. Within the nucleus, it could activate the transcription of genes encoding the inhibitors of the cell cycle. These mechanisms might be contributed in eliciting the observed downregulation of the antiapoptotic and proliferative markers as a consequence of doxorubicin treatment in HCC bearing rats.

Of note, the combination between doxorubicin and selenium nanoparticles revealed no treatable action against hepatocellular carcinoma as shown in the data of the present study. The exact mechanisms behind this effect are presently unknown.

CONCLUSION

The present research study has brought about compelling evidence favoring a potent role of selenium nanoparticles in repression of hepatocellular carcinoma in the experimental model. The therapeutic and protective effects afforded by selenium nanoparticles in this concern was likely attributable to their hepatoprotective potential, antitumor activity, apoptotic property and antiproliferative capacity. Thus, selenium nanoparticles may be good candidates against hepatocellular carcinoma. However, further clinical studies including detailed toxicity analyses are needed to determine the usefulness of these nanoparticles in the treatment of cancer.

REFERENCES

- [1] H Zeng; GF Combs. *J. of Nutronal Biochemistry*, **2008**, 19, 1-7.
- [2] J Zhang; X Wang; T Xu. *Toxicological Sciences*, **2008**, 101, 22-31.
- [3] J Zhang; H Wang; X Yan; L Zhang. *Life Sci*, **2005**, 76, 1099-1109.
- [4] SM Lippman; PJ Goodman; EA Klein; HL Parnes; IM Thompson; AR Kristal; RM Santella; JL Probstfield; CM Moinpour; D Albanes; PR Taylor; LM Minasian; A Hoque; SM Thomas; JJ Crowle; JM Gaziano; JL Stanford; ED Cook; NE Fleshner; MM Lieber; PJ Walther; FR Khuri; GG Schwartz ; LG Ford; CA Coltman. *J. Natl. Cancer Inst.*, **2005**, 97, 94-102.
- [5] S Petcharin; H Sriplung; S Deerasamee. *Asian Pacific J. Cancer Prev.*, **2004**, 5, 118-125.
- [6] S Hirohashi; KG Ishak; M Kojiro; et al. Hepatocellular carcinoma in: Hamilton SR and Aaltonen LA, (eds.) Pathology and Genetics of Tumours of the Digestive System, International Agency for Research on Cancer, Lyon, **1999**, pp. 159-172.
- [7] A Fritz; et al. International Classification of Disease for Oncology, 3rd Ed., World Health Organization, Geneva, **2000**.
- [8] C Dwivedi; CP Shah; K Singh; M Kumar; PN Bajaj. *Journal of Nanotechnology*, **2011**, 2011, 1-6.
- [9] A.O.A.C. Official methods of analysis, 16th Ed., Association of official analysis, Wahington DC, **1995**.
- [10] KY Karimov; FK Inoyatova; MT Mukhamedova. *Exp. Toxicol. Pathol.*, **2003**, 55, 17-19.
- [11] JM Barnes; GE Paget. *Prog. Med. Chem.*, **1965**, 18-38.
- [12] S Reitman; S Frankel. *Am. J. Clin. Pathol.*, **1957**, 28,56.
- [13] A Belfield; DM Goldberg. *Enzyme*, **1971**, 12, 561-568.
- [14] MK Schwartz . Tumor markers in diagnosis and screening. In: Ting SW, Chen JS, Schwartz MK, Eds. Human tumor markers, Amsterdam, **1987**, pp. 3-16.
- [15] AM Alnajjar; HA Elsiey. *Hepatoma Research*, **2015**, 1,119-124.
- [16] G Willimsky; K Schmidt; C Loddenkemper; J Gellermann; T Blankenstein. *The Journal of Clinical Investigation*, **2013**, 123, 1032-1043.
- [17] HO El Mesallamy; NS Metwally; MS Soliman; KA Ahmed; MM Abdel Moat Y. *Cancer Cell International*, **2011**, 11, 38.

- [18] KH Kim; GY Oudit; PH Backx. *Journal of Pharmacology and Experimental Therapeutics*, **2008**, 324, 160–169.
- [19] EE Essick; F Sam. *Oxidative Medicine and Cellular Longevity*, **2010**, 3, 168–177.
- [20] D Cosan; A Basaran; HV Gunes; I Degirmenci; E Aral. *Folia Histochem Cytobiolo*, **2008**, 46, 367–372.
- [21] HH Ahmed; El-S ME Mahdy; HA El-Mezayen; RM Hussien. *Journal of Chemical and Pharmaceutical Research*, **2014**, 6, 662-671.
- [22] G Kumar; GS Banu; MR Pandian. *Indian J. Clin. Biochem.*, **2007**, 22, 105-108.
- [23] I Ozardali; M Bitiren; AZ Karakilcik; M Zerir; N Aksoy; D Musa. *Exp. Toxicol. Pathol.*, **2004**, 56, 59-64.
- [24] B Chen; M Ning; G Yang. *Molecules*, **2012**, 17, 4672-4683.
- [25] HH Ahmed; WG Shousha; AB Shalby; HA El-Mezayen; NN Ismaiel; NS Mahmoud. *Tumor Biol.*, **2015**, 36, 1667–1678.
- [26] Y Song; S Jin; L Cui; X Ji; F Yang. *Molecules*, **2013**, 18, 7179-7193.
- [27] A Singhal; M Jayaraman; DN Dhanasekaran; V Kohli. *Crit. Rev. Oncol. Hematol*, **2012**, 82, 116–140.
- [28] B Sun; M Karin. *Oncogene*, **2008**, 27, 6228–6244.
- [29] BB Aggarwal; KB Harikumar. *Int. J. Biochem. Cell Biol.*, **2009**, 41, 40-59.
- [30] W Cui; SX Hu; Z Tang; K Hu. *J. Cancer Mol*, **2007**, 3, 49-54.
- [31] R Zimmer; P Thomas. *Cancer Res.*, **2001**, 61, 2822–2826.
- [32] GM Macnab; JM Urbanowicz; MC Kew. *Br. J. Cancer*, **1978**, 38, 51-54.
- [33] P Thomas; DA Hems. *Biochem. Biophys. Res. Comm.*, **1975**, 67, 1205-1209.
- [34] W Jiang; C Jiang; H Pei; L Wang; J Zhang ; H Hu; J Lü. *Mol. Cancer Ther.*, **2009**, 8, 682-691.
- [35] JG Liu; HJ Zhao; YJ Liu; YW Liu; XL Wang. *J. Trace Elem. Med. Biol.*, **2012**, 26, 255-261.
- [36] SM Hamdy; AM Abdel Latif; EA Dress; SM Soliman. *Toxicol. Ind. Health*, **2012**, 28, 746-757.
- [37] A Bhattacharya; SG Turowski; ID San Martin; A Rajput; YM Rustum; RM Hoffman; M Seshadri. *Anticancer Res*, **2011**, 31, 387-93.
- [38] K El-Bayoumy. *Mutation Research*, **2001**, 475, 123-139.
- [39] M Moustafa; M Morsi; A Hussein; E AL-Abd; N Abdel-Moneim. *Turk. J. Cancer*, **2005**, 35, 5–11.
- [40] K Kusuzaki; H Shinjo; H Murata; H Takeshita; S Hashiguchi; T Nozaki; K Emoto; T Ashihara; Y Hirasawa. *Anticancer Res.*, **2000**, 20, 3813–6.
- [41] H Clevers. *Cell*, **2006**, 127, 469–480.
- [42] T Suzuki; H Yano; Y Nakashima; O Nakashima; M Kojiro. *J. Gastroenterol. Hepatol.*, **2002**, 17, 994-1000.
- [43] H Zhu; XP Chen; WG Zhang; SF Luo; BX Zhang. *World J. Gastroenterol.*, **2005**, 11, 3855-3859.
- [44] I Tamm; Y Wang; E Sausville; DA Scudiero; N Vigna; T Oltersdorf; JC Reed. *Cancer Res.*, **1998**, 58, 5315-5320.
- [45] T Yamanaka; K Shiraki; K Sugimoto; T Ito; K Fujikawa; M Ito; K Takase; M Moriyama; T Nakano; A Suzuki. *Hepatology*, **2000**, 32, 482–490.
- [46] A Nesterov; X Lu; M Johnson; GJ Miller; Y Ivashchenko; AS Kraft. *J. Biol. Chem.*, **2001**, 276, 10767-10774.
- [47] WH Hu; H Johnson; HB Shu. *J. Biol. Chem.*, **1999**, 247, 30603-30610.
- [48] T Umemura; S Kai; R Hasegawa; K Keita; Y Kitamura; A Nishikawa; M Hirose. *Carcinogenesis*, **2003**, 24, 1105-1109.
- [49] J Pizem; VF Marolt; B Luzar; A Cor. *Pflugers Arch.*, **2001**, 442, 174-176.
- [50] OO Ogunwobi; C Liu. *Clin. Exp. Metastasis*, **2011**, 28, 721-731.
- [51] H Luo; Y Yang; F Huang; F Li; Q Jiang; K Shi; C Xu. *Cancer Lett.*, **2012**, 315, 78–85.
- [52] JY Chun; Y Hu; E Pinder; J Wu; F Li; AC Gao. *Mol. Cancer Ther.*, **2007**, 6, 2572-80.
- [53] W Fang; A Han; X Bi; B Xiong; W Yang. *Int. J. Cancer*, **2010**, 127, 32-42.
- [54] M Zhang; J Yang; F Li. *J. Exp. Clin. Cancer Res.*, **2006**, 25, 391-402.
- [55] Y Hu; GH McIntosh; RK Le Leu; R Woodman; GP Young. *Cancer Res.*, **2008**, 68, 4936-44.
- [56] A Baines; M Taylor-Parker ; AC Goulet; C Renaud; EW Gerner; MA Nelson. *Cancer Biol. Ther.*, **2002**, 1, 370-374.
- [57] H Luo; F Wang; Y Bai; T Chen; W Zheng. *Colloids Surf. B. Biointerfaces*, **2012**, 94, 304-308.
- [58] E Czeczuga-Semeniuk; S Wolczyński; M Dabrowska; J Dziecioł; T Anchim. *Folia Histochem. Cytobiol.*, **2004**, 42, 221-227.
- [59] CF Thorn; C Oshiro; S Marsh; T Hernandez-Boussard; H McLeod; TE Klein; RB Altman. *Pharmacogenet. Genomics*, **2011**, 21, 7, 440–446.
- [60] SV Kalivendi; S Kotamraju; H Zhao; J Joseph; B Kalyanaraman. *The Journal of Biological Chemistry*, **2011**, 276, 47266–47276.
- [61] B Denard; C Lee; J Ye. *Elife*, **2012**, 1, 90.