



Scholars Research Library

Der Pharmacia Lettre, 2016, 8 (1):161-168
(<http://scholarsresearchlibrary.com/archive.html>)



Evaluation of the wound-healing potency of *Citrus sinensis* in Wistar albino rats

Senthamil Selvi Ramasamy and Anusha Bhaskar*

Department of Biochemistry, Centre for Research and Development, PRIST University, Vallam Thanjavur

ABSTRACT

To evaluate the wound healing efficacy of the methanolic extract of the peel extract of *Citrus sinensis*. The wound healing activity of *C. sinensis* (5% and 10% w/w) on Wistar albino rats were studied using three wound models viz., excision, incision and dead space. The study included breaking strength in incision model, granulation tissue dry weight, breaking strength and collagen content in dead space wound model, percentage of wound contraction and period of epithelialization in excision wound model. The granulation tissue formed on days 4, 8, 12 and 16 (post-wound) was used to estimate total collagen, hexosamine, protein, DNA and uronic acid. The tissues were subjected to histological studies and the tissue regeneration was evaluated. Data analysis was done using Analysis of Variance (ANOVA) test $P < 0.05$ was considered statistically significant. The biochemical and histological studies showed that collagen synthesis was increased at the wound site. There was a concomitant increase in total protein and DNA suggesting increased cellular proliferation. The extract treated wounds were found to heal much faster than the controls ($p < 0.001$), the rate of wound contraction was significantly ($p < 0.001$) increased compared to control wounds. Wet and dry granulation tissue weights in a dead space wound model increased significantly ($P < 0.001$). There was a significant increase in wound closure rate, tensile strength, dry granuloma weight, wet granuloma weight and decrease in epithelization period in *C. sinensis* treated group as compared to control and standard drug-treated groups. The methanolic extract of *C. sinensis* had greater wound –healing activity than the nitrofurazone ointment.

Keywords: *C. sinensis*, wound healing, collagen, epithelization, granuloma

INTRODUCTION

Wound healing is a dynamic and complex process controlled by a number of factors. Once the protective barrier of epidermis and dermis are broken, the physiologic process of wound healing is immediately carried on. Wound healing involves distinct overlapping phase of coagulation, inflammation, proliferation and tissue remodeling [1-3]. After a tissues damage the healing process is self-motivated where homeostasis is attained among the endothelial cells, thrombocytes, coagulation and fibrinolysis. It also regulates the fibrin deposits at the wound site. During this process, a set of complex biochemical events takes place in a closely orchestrated cascade to repair damage. The goal of wound treatment is fast and scars less healing. There is no wide accepted regimen to both improve wound healing and reduce scar formation. The current treatments [4], which include chemical drugs, pressure therapy, laser therapy, radiation and surgical operations could not achieve the satisfied results.

The aim of treating a wound is to shorten the time required for healing and to minimize the undesired consequences. Plants have the immense potential for the management and treatment of wounds. These natural agents induce

healing and regeneration of lost tissue by some mechanism. The medicinal value of the plants lies in bioactive photochemical constituents that produce definite physiological action on the human body [5]. These constituents include various chemical families like alkaloids, essential oils, flavonoids, tannins, terpenoids, saponins and phenolic compounds [6].

Therefore, plants or chemical entities derived from plants need to be identified and formulated for treatment and management of wounds. Herein we have experimentally evaluated the wound healing potential of a plant of the *Citrus* sp. viz., *Citrus sinensis*. The peel of citrus fruits is a rich source of flavonones and many polymethoxylated flavones, which are rare in other plants. These compounds play an important role in the medicinal property of the plant.

MATERIALS AND METHODS

Plant Material and preparation of extract

Citrus sinensis fruits were obtained from market of Thanjavur district, Tamil Nadu, India. The peels of the fruit were shade-dried at room temperature, pulverized by a mechanical grinder, sieved through 40-size sieve mesh. 500 g of fine powder was suspended in 1500 ml of methanol for 24h at room temperature. The mixture was filtered using a fine muslin cloth followed by filter paper (Whatmann No:1). The filtrate was placed in a water bath to dry at 40 °C and the final methanol-free clear residue was used for the study.

Ointment Formulation

Two types of ointment formulations will be prepared from the extract of *Citrus sinensis* 5% to 10% (w/w), whereas 5 or 10g of the extract will be incorporated into 100g of simple ointment base British Pharmacopoeia (B.P) respectively. Nitrofurazone ointment (0.2% w/w, Smith Kline-Beecham Pharmaceuticals Bangalore, India) will be used as a standard drug for comparing the wound-healing potential of the extract.

Qualitative Phytochemical Evaluation

The peel extract was subjected to qualitative tests by adopting standard procedure for the identification of phytoconstituents present in it viz., alkaloids, carbohydrates, glycosides, phytosterols, fixed oils, phenolic compounds, proteins, free amino acids, gums, mucilage, flavonoids, terpenoids, lignins and saponins.

Animals

Wistar albino rats (150 – 250 g body weight) were used after an acclimatization period of 7 days to the laboratory environment. They were provided with food and water *ad libitum*. The work was carried out in CPCSEA approved (PRIST/IAEC/Project/CRD/01-2013-2014) Animal House of PRIST University, Thanjavur.

Study Design

Four groups of animals were studied each containing six animals. The drug treatment was as follows:

Group I: Received simple ointment base and served as normal control group.

Group II: Received alcoholic extract ointment 5% w/w topically on wound created on the dorsal back of rats daily till the wounds completely healed.

Group III: Received alcoholic extract ointment 10% w/w w topically on wound created on the dorsal back of rats daily till the wounds completely healed.

Group IV: Received reference standard 0.2% w/w nitrofurazone ointment.

Excision Wound

The rats will be inflicted with excision wounds as described by Morton and Malone [7] under light ether anesthesia. One excision wound will be made by cutting away a 500 mm² full thickness of skin from the depilate area; the wound will be left undressed to open environment. The animals will be divided into four groups of five each. The animals of group I were left untreated and considered as control, group II served as reference standard and treated with 0.2% w/w nitrofurazone ointment. Animals of group III and IV were treated with 50 mg of ointment prepare from 5% to 10% (w/w) of methanolic extract of *Citrus sinensis*. The ointment was topically applied once a day, starting from the day of the operation, till complete epithelization. This model was used to monitor wound contraction and wound closure time Wound contraction will be calculated as percentage reduction in wound area. The progressive changes in wound area will be monitored planimetrically by tracing the wound margin on graph

paper every alternate day. The period of epithelialization will be calculated as the number of days required for falling of the dead tissue remnants of the wound without any residual raw wound.

Incision Wounds

In incision wound model, 6cm long paravertebral incisions were made through the full thickness of the skin on either side of the vertebral column of the rats as described by Lee [8]. The wounds will be closed with interrupted sutures, 1cm apart. The animals of group I were left untreated (control), the group II served as reference standard and received 0.2% w/w nitrofurazone ointment, animals in groups III and IV were treated with ointment prepared from 5% to 10% w/w methanolic extract of *C. sinensis* peel extract. The ointment was topically applied once a day. The sutures were removed on the 7th day. Wound-breaking strength was measured in anesthetized rats on the 10th day after wounding.

Dead Space Wounds

The animals will be divided into three groups of 6 rats in each group. Group I served as the control, which received 2 ml of 1% carboxy methyl cellulose (CMC) orally. The animals of group II and III received oral suspension of *C. sinensis* (5% w/w and 10% w/w) for 10 days. Under light ether anesthesia, dead space wound was created by subcutaneous implantation of sterilized cylindrical grass liths (2.5 x 0.3 cm), one on either side of the dorsal paravertebral surface of the rats [9]. On the 11th post-operative day, the dead space wound was excised. Wet weight was recorded and tensile strength determined [10]. The granuloma was dried in an oven at 60 °C and the dry weight noted. The tensile strength was measured using a tensiometer.

Measurement of Healing

Tensile strength, the force required to open a healing skin wound, was used to measure healing. This will be measured using a tensiometer. It is designed on the same principle as the thread tester used in the textile industry. It consists of 6 x 12 inch board with one post of 4 inch long, fixed on each side of the longer ends. The board was placed at the end of a table. A pulley with a bearing was mounted on the top of one of the posts. An alligator clamp with 1 cm width, was tied on the tip of the post without pulley. Another alligator clamp will be tied on a piece of fishing line with a 1 L polyethylene bottle tie on the other end. The excised granuloma tissue was placed on a stack of paper towels that will be adjusted so that the polyethylene bottle freely hangs in the air. Water added to the polyethylene bottle was weighed and this is considered as the tensile strength of the wound.

Collection of granulation tissue from Dead Space Wound

Granulation tissues from control and test groups was collected and washed in cold saline (0.9% NaCl) to remove the blood tissues and stored for analyses. The granulation tissues were lyophilized for collagen and hexosamine analysis.

Biochemical Estimation

Protein and DNA of wet granulation tissues will be extracted in 5% trichloroacetic acid (TCA) as per Porat *et al* [11]. 10ml of 5% TCA was added to the tissue (100mg wet wt. of tissue) and kept at 90^oC for 30 min in a water bath to extract protein and DNA. The solution was centrifuged and the supernatant used to estimate DNA by the method Burton [12] and protein by the method of Lowry *et al* [13]. To estimate collagen and hexosamine, the defatted tissue samples in chloroform : methanol (2:1) and dried in acetone. Collagen will be estimated by the method of Woessner [14], whereas hexosamine and uronic acid will estimated by the methods of and Elson and Morgon [15] and Schiller *et al* [16], respectively.

Histopathological examination

Histopathological examination was performed to study the tissue architecture of the tissue isolate from the healed skin of the rats. The cross-sectional full-thickness skin specimens and deep granulation tissues from the implanted type were collected on the 16th day of the experiment for the histopathological alterations. Samples were fixed in 10% buffered formalin, processed and blocked with paraffin sectioned into 5µm thick sections. The sections will be stained with Hematoxylin and Eosin stain (HE), Van Gieson's stain (VG) and Toluidine blue stain (TB). Hematoxylin and Eosin stain sections and Van Gieson's stain sections will show collagen deposition and toluidine blue stain sections will check for metachromatic staining of mast cells.

Statistical Analysis

Data are expressed as mean±SEM and subjected to Analysis of Variance (ANOVA) test for comparison.

RESULTS

In the preliminary phytochemical evaluations of all the extracts of the *Citrus sinensis* peel obtained from alcohol, aqueous, petroleum ether, chloroform and ethyl acetate were evaluated for the presence of alkaloids, glucosides, steroids, fixed oils, fats, terpenes, tannins and flavonoids. The results showed the presence of flavonoids, fixed oils, tannins and alkaloids in all the extracts.

Wound healing is the process of repair following injury to the skin and other soft tissues. It is a complex and dynamic process of restoring cellular structures and tissue layers in damaged tissue as closely as possible to its normal and original state [17]. Topical application of *C. sinensis* improved wound contraction and closure and the effects were distinctly visible starting from 4th post-wounding day. Wound healing activity was observed in all three models viz. excision, incision and dead space wound.

Table 1 and Fig 1 show the wound contracting ability of the extract ointment was significantly greater ($P < 0.01$) than control as well as reference standard (NFZ ointment). The extract ointment produced complete healing at 16th day and 18th day with 5 and 10 % w/w extract ointment respectively. The upper layer of the wound was surgically removed and subjected to histological studies. Histological examination of the haematoxylin and eosin stained tissue of the rat wounds treated with plant extract and nitrofurazone ointment have led to reduce scar formation and enhanced fibroblast proliferation, angiogenesis, keratinisation and epithelialisation as compared to control group (Figure 2).

In the incision wound model tensile strength and granuloma weight were determined, a significant increase ($P < 0.01$) in breaking strength (g) was observed in rats treated with 5% and 10% *C. sinensis* extract ointment, respectively when compared to controls treated with NFZ ointment (Table 2). The wound which was untreated (Control group) had the minimum strength (17.5 ± 2.1 g) as compared to the 5% treated (42.5 ± 7.45) which showed better values than the 10% ointment treated and it was even better than the nitrofurazone treated (31.5 ± 1.25). This observation confirms that the methanolic extract of *Citrus sinensis* possess very good wound healing properties. Table 3 shows the effect of *C. sinensis* ointment on the dead space wound. Compared to the control group of animals, 5% extract treated animals showed significant increase in dry weight of granulation tissue, wet weight granulation tissue and breaking strength.

The biochemical estimation of collagen, hexosamine, DNA, protein and uronic acid were carried out on 4, 8, 12 and 16 days of treatment (Table 4). The DNA content showed a three-fold increase within the 8th day and a maximum on the 12th day, proteins also showed a similar increase suggesting that tissue repair increased with treatment using the plant extract. Uronic acid, hexosamine and total collagen were also found to be significantly ($P < 0.001$) increased with treatment when compared to the controls.

Histology of granulation tissue of control rat showed mononuclear inflammatory cells, scattered fibroblasts and few proliferating vasculature in granulation tissue. The rats treated with *Citrus sinensis* both 5% and 10% ointment showed abundance of eosinophilic collagen tissue and neovascularisation with inflammatory cells indicative of healing by fibrosis.

DISCUSSION

The phyto-constituents present in the plant extract may be responsible for wound contraction and increased rate of epithelialization observed. The wound breaking strength is determined by the rate of collagen synthesis and more so by the maturation process where there is covalent binding or collagen fibrils through inter- and intra-molecular cross-linkings [18]. In the present study, a significant increase in tensile strength on the 12th day was observed in the test group as compared to the control group. The increase in tensile strength of treated wounds may be due to the increase in collagen concentration, hexosamine, uronic acid and stabilization of the fibers by increase in protein content.

Figure 1: Photographic representation of rate of wound contraction area on different group of post excision days of control, *Citrus sinensis* (5% to 10% w/w methanolic), and 0.2% w/w Nitrofurazone ointment treated rats.


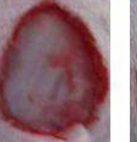
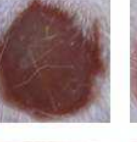













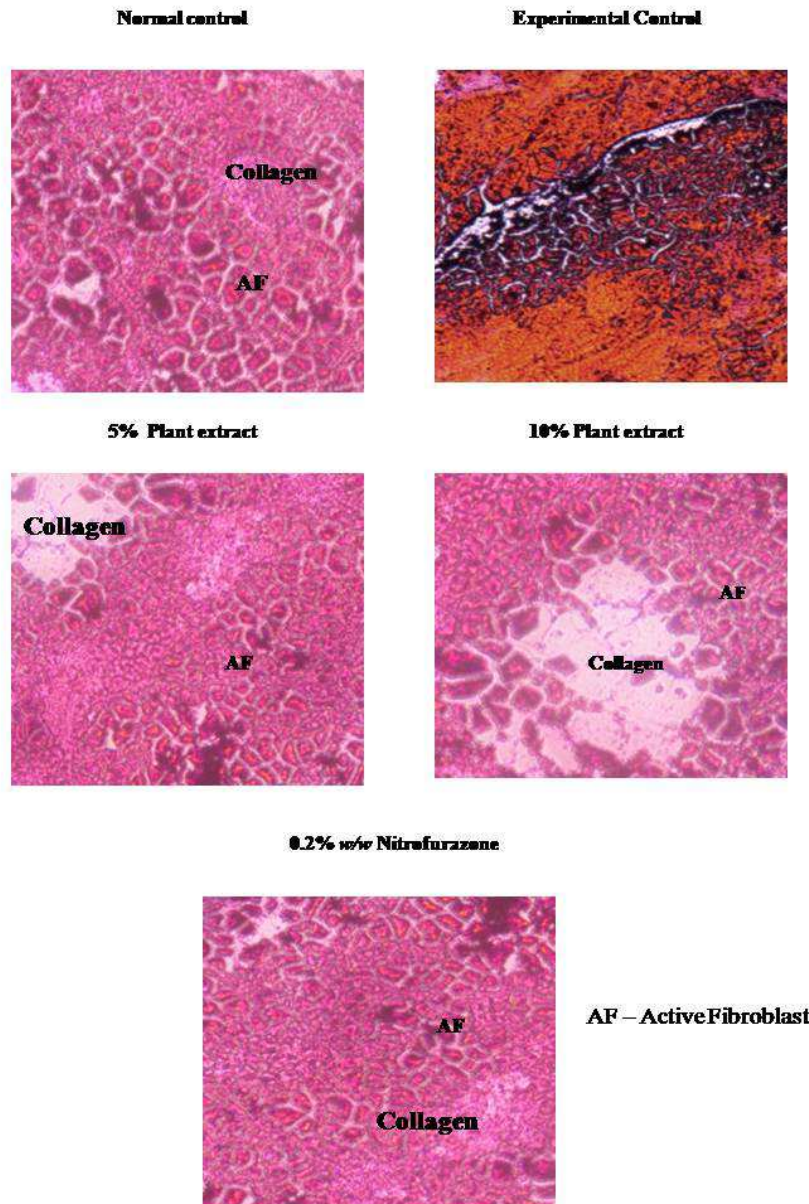
Days of Wound	Experimental Control	5% Plant Extract	10% Plant Extract	Nitrofurazone
0th Day				
2nd Day				
6th Day				
8th Day				
10th Day				
13th Day				
16th Day				
18th Day				

Figure 2: Histopathology of skin at day 16 stained with H&E and VG & TB (40x). (a) Skin of Normal control rat showing normal architecture of skin, (b) Rats showing tissue ruptured and damaged. (c & d) 5% and 10% *C.sinesis* treated rats showing healed skin structures with well-formed, near to normal epidermis, active fibroblast and collagen tissue within the dermis. (e) 0.2% w/w Nitrofurazone treated rats showing healed skin structures with collagen and fibroblast level were less.



Collagen is a major protein of the extracellular matrix and is the component that ultimately contributes to wound strength. The healing process depends, to a large extent, on the regulated biosynthesis and deposition of new collagens and their subsequent maturation[19]. Assessment of collagen content in granulation tissues of control and experimental wounds clearly suggests that *C. sinensis* enhances collagen synthesis and deposition. The amount of collagen may be increased in total cell number as a result of increased cell division.

Table 1: Effect of *Citrus sinensis* extract ointment on excision model in rats

Post Wounding days	Wound Area (mm ²)			
	Control group	Reference group nitrofurazone ointment (0.2% w/w)	Treatment group methanolic <i>C. sinensis</i> extract ointment (5% w/w)	Treatment group methanolic <i>C. sinensis</i> extract ointment (10% w/w)
0	510 ±10.3 (0.0)	512 ±15.2 (0.0)	510 ± 16.0 (0)	513 ± 19.8 (0)
2	457 ±12.4 (10.4)	447 ± 20.6 (12.7)	375 ± 19.5 (26.4)	436 ± 15.8 (15)
4	425 ±18.2 (16.6)	350 ± 25.4* (31.6)	332 ± 17.9* (35)	380 ± 18.8* (26)
6	401 ±15.6 (21.3)	241 ±22.4** (52.9)	270 ± 12.3* (47)	300 ± 15.4** (41.5)
8	343 ±11.2(32.7)	135 ±18.6** (75.6)	156 ± 10.5** (69.4)	153 ± 10.8** (70)
10	300 ±12.4(41.2)	124 ±13.6** (75.8)	108 ± 8.5** (78.8)	95 ± 6.2** (81)
12	265 ±10.9(48.0)	85 ±8.5** (83.3)	45 ±4.4** (91.2)	47 ± 3.1** (91)
14	248 ±12.6(51.0)	41 ±3.4** (92.0)	20 ±3.0** (96)	20 ± 2.3** (96)
16	230 ±14.5(54.9)	11 ±0.8** (97.8)	0.0** (100)	10 ± 0.04* (98.6)
18	220 ±12.9(56.8)	0.0** (100.0)	0.0** (100)	0.0** (100)

Values are means ±SEM (n=6). Figure in parentheses indicates percentage of wound contraction. *P<0.01 as compared to control by ANOVA, **P<0.001 as compared to control by ANOVA

Table 2 : Comparison of effect of *C. sinensis* extract ointment on incision wound in rats

Treatment	Granuloma weight (mg)	Breaking strength (g)
Control group (no treatment)	234.5 ± 9.12	17.5 ± 2.1
Treatment group <i>C. sinensis</i> extract ointment (5% w/w)	362.6 ± 18.2*	42.5 ± 7.45*
Treatment group <i>C. sinensis</i> extract ointment (10% w/w)	398.2 ± 13.5*	38.9 ± 2.3*
Reference group Nitrofurazone ointment (0.2% w/w)	340 ± 13.2	31.5 ± 1.25

Values are mean ± SEM (n=6), *P<0.01 as compared to control by ANOVA

Table 3: Comparison of effect of *C. sinensis* extract ointment on dead space wound in rats

Parameters	Control group	<i>C. sinensis</i> ointment 5% treated group	<i>C. sinensis</i> ointment 10% treated group
Wet granuloma weight (mg)	208.6 ± 9.5	485.5 ± 25.2*	390.8 ± 12.3*
Dry granuloma weight (mg)	35.6 ± 2.0	105.7 ± 8.9*	84.2 ± 6.2*
Tensile strength (g)	375 ± 20.2	580.4 ± 42.5*	480.2 ± 31.2*

Values are mean ± SEM (n=6), *P<0.01 as compared to control

Table 4: Effect of *C. sinensis* on various biochemical parameters

Test group	4 days	8 days	12 days	16 days
DNA (mg/100 mg wet tissue)				
Control	1.62±0.24	5.42±0.76	4.85±0.80	3.62±0.60
Experimental	2.25±0.30*	7.05±0.90** a	7.95±0.92*	2.78±0.54
Protein (mg/100 mg wet tissue)				
Control	3.75±0.52	4.25±0.74	6.20±0.85	5.65±0.80
Experimental	5.05±0.73*	6.95±0.85** a	8.35±0.90*	4.60±0.78
Total collagen (mg/100 mg dry tissue)				
Control	2.03±0.87	4.31±1.28	3.80±1.25	3.60±1.15
Experimental	4.45±1.41*	7.80±1.53** a	8.92±1.52** b	2.60±0.92
Hexosamine (g/100 mg dry tissue)				
Control	762±35	545±40	432±36	352±29
Experimental	920±80*	998±55 ** b	975±57** a	320±23
Uronic acid (g/100 mg dry tissue)				
Control	96.7±1.20	90±0.93	84.52±0.98	85.91±0.95
Experimental	99±1.46*	135±2.58** b	97±1.30** a	82.74±0.91

Values are mean ± S.D. of six observations. a = 0.05; b = 0.01 as compared with corresponding control using non-parametric Mann-Whitney U-test.

* p < 0.01 as compared using Students unpaired t-test.

** p < 0.001 as compared using Students unpaired t-test.

The maturation and remodeling phase of wound healing cell population were decreased and collagen deposition will be increased in granulation tissues which form the scar. Figure 2 shows the histopathology results of tissues when treated with *C. sinensis*, this further substantiates the biochemical findings and suggests that 5% plant extract was better than the 10% and the collagen deposition clearly indicates the wound healing.

Hexosamine and uronic acid are matrix molecules, which act as ground substrate for the synthesis of new extracellular matrix. It is reported that there is an increase in the levels of these components during the early stages of wound healing, following which normal levels are restored[20]. The increase in DNA content in the treated wounds indicates cellular hyperplasia. A similar trend was observed in *C. sinensis* treated wounds wherein the levels of hexosamine and uronic acid increased up to day 8 post-wounding and decreased thereafter.

Plant extracts have played a vital role in wound healing since time immemorable. The availability, effectiveness, non-toxicity and necessarily the absence of side effects have made plants as potential agents of wound healing. When these plants extracts are applied topically on the wound site they are effective in facilitating faster wound contraction. This may be because of the larger availability at the wound site. In our study we conclude that topical administration of *C. sinensis* methanol extract accelerates scar formation and promotes various stages of wound healing such as fibroplasias, collagen synthesis, wound contraction and epithelization.

Acknowledgments

The authors wish to express their gratitude to Defence Research Development Organization (DRDO), India for financial support extended for carrying out this work.

REFERENCES

- [1] Mutsaers SE, Bishop JE, McGrouther G, Laurent GJ. *Int J Biochem Cell Biol.*, **1997**; 29: 5–17.
- [2] Singer AJ, Clark RA. *N Engl J Med.*, **1999**; 341: 738–746.
- [3] Falanga V. *Lancet* **2005**; 366: 1736–1743.
- [4] Wolfram D, Tzankov A, Pu" lzl P, Piza-Katzer H. *Dermatol Surg* **2009**; 35: 171–181.
- [5] Akinmoladun AC, Ibukun EO, Afor E, Akinrinlola BL, Onibon TR, Akinboboye AO, Obuotor EM, Farombi EO. *African J Biotech.* **2007**; 6(10): 1197–1201.
- [6] Edeoga HO, Okwu D E, Mbaebie BO. *African J Biotech.* **2005**; 4(7):. 685–688.
- [7] Morton JJP, Malone MH. *Arch Int Pharmacodyn.*, **1972**; 196:117-126.
- [8] Lee KH. *Journal of Pharmaceutical Sciences.* **1968**; 57 (6): 1042-1043.
- [9] Turner RA. Anabolic, androgenic and antiandrogenic agents. In: Turner RA editor. *Screening Methods in Pharmacology.* Chapter 33, New York and London Academic Press, **1965**. p. 244-246.
- [10] Hassan SW, Abubakar MG, Umar RA, Yakuba AS, Maishanu HM, Ayeni G. *J Pharmacol Toxicol.*, **2011**; 6: 124 – 132.
- [11] Porat S, Roussa M, Shosan S. *Journal of Bone and Joint Surgery*, **1980**; 62: 208.
- [12] Burton KA.. *Biochemical Journal*, **1956**; 62: 315–323.
- [13] Lowry OH, Rosebrough NJ, Farr AL, Randall RT. *Journal of Biological Chemistry*,**1951**; 193: 265–276.
- [14] Woessner JR. *Archives of Biochemistry and Biophysics.* **1979**; 93: 440–447.
- [15] Elson LA, Morgan WTJ. *Proc.Soc. Exp.Biol.*, **1993**; 58: 97-100.
- [16] Schiller S, Slover G, Dorfman AA. *Journal of Biological Chemistry*, **1961**; 36, 983–985.
- [17] Clark RA. *J Am Acad Dermatol* **1985**;13: 701-725
- [18] Shanbag TV, Sharma C, Sachidananda A, Kurady BL, Smita S, Ganesh S. *Ind J Physiol Pharmacol.*, **2006**; 50: 384 – 390.
- [19] Hassan SW, Abubakar MG, Umar RA, Yakubu AS, Maishanu HM, Ayeni G. *J Pharmacol Toxicol.*,**2011**; 6: 124- 132.
- [20] Kumar R, Katoch SS, Sharma S. *Ind J Exp Biol.*, **2006**; 44: 371 – 376.