



Scholars Research Library

Annals of Biological Research, 2011, 2 (6):580-585
(<http://scholarsresearchlibrary.com/archive.html>)



Scholars Research
Library
ISSN 0976-1233
CODEN (USA): ABRNBW

Effects of gamma irradiation on histomorphology of different organs in rats

Navid Hosseini Mansoub^{1*} and Ali Heidari Sarvestani²

¹Mahabad Branch, Islamic Azad University, Mahabad, Iran

²Department of Cardiology, Ahvaz Jundishapur University of Medicine, Faculty of Medicine, Iran

ABSTRACT

An experiment was conducted to evaluate the effects of cobalt radiation on histomorphology changes in heart, brain, kidney, spleen, lung and liver of Wistar rats weighing 160 to 180 gr. A total of 100 rats were divided into 4 groups with 25 rats each. T1) First group as control group did not receive any radiation, T2) was irradiated with 6Gy, T3) was irradiated with 8Gy, T4) was irradiated with 14Gy. Results demonstrated dosage dependent changes in different parts of the brain tissue. Histopathological studies of the central nervous system revealed radiation-induced lesions early after exposure with congestion and edema. The renal tissues were subjected to histological processing, and then studied. Histopathological studies revealed glomerular and tubular changes with infiltration of the neutrophils and other leukocytes. More irreversible changes included mesangial matrix and cell number increase in glomeruli. The muscular strings of heart were narrowed and became atrophic which led to the gap between heart muscular strings (edema) in groups 2 and 3 while, rupture and necrosis can be seen in group 4. Areas of necrotic hepatocytes and cell swelling were seen in G3 and G4. But in the group 4 severe congestion was seen. Also pathological study of spleen showed that necrosis in some parts of the spleen in 3 exposed groups and fibrinoid degeneration in the central splenic vein in group. Studies of the lung revealed radiation-induced edema, hyperemia can be seen in all the 3 groups and goes up as the dosage increases. Also, the thickening of alveolar walls through penetration of unicellular e.g. lymphocytes and macrophages are observed in animals of groups 3 and 4.

Key words: Cobalt, Irradiation, rat, necrosis, histomorphology, gamma irradiation.

INTRODUCTION

Radiation may be used as adjuvant or primary therapy in a variety of tumors in the chest, abdomen and pelvis. Therapeutic radiation affects not only malignant tumors but also

surrounding normal tissues. The risk of injury depends on the size, number and frequency of radiation fractions, volume of irradiated tissue, duration of treatment, and method of radiation delivery. Combination of surgery, chemotherapy, and radiation treatment are the mainstay of the modern cancer therapy [1]. Radiation damage is generally divided into early and late stages. The early stage, occurring 1 to 4 months after treatment, is that of radiation pneumonitis. The severity of radiation pneumonitis increases with increased volume of tissue radiated [2], increased radiation dose, and faster rate of administration [3-5]. Radiation pneumonitis is generally not radiologically apparent after doses less than 20 Gy [6]. Necrosis and inflammation were the key features of high dose radiation injury. Radiation necrosis is coagulative and predominantly affect white matter. The coagulative necrosis is due to small artery injury and thrombotic occlusion. It has been hypothesized that irradiation of the brain has an additional risk factor for the development direct injury to glial cells. Exposure to the moderately low doses of cobalt 60 radiation has resulted in decreased body weight [7-9]. Studies from exposed human and animals indicate that radiation from cobalt can affect a wide variety of tissues with greater levels of cellular divisions [10]. Necrosis and inflammation were the key features of high dose radiation injury. Exposure to the moderately low doses of cobalt 60 radiation has resulted in decreased body weight [11]. Irradiation of the kidney may occur during TBI, which is a form of direct injury, or as a consequence of irradiation of nearby structures, thus causing radiation nephritis [12].

MATERIALS AND METHODS

A total of 100 rats were divided into 4 groups with 25 rats each. T1) First group as control group did not receive any radiation, T2) was irradiated with 6Gy, T3) was irradiated with 8Gy, T4) was irradiated with 14Gy.. Animals were housed under standardized conditions for light and temperature. A commercially prepared diet and clean drinking water were provided ad libitum. The rats were anesthetized with an intra-peritoneal injection of mixture of ketamin(80mg/kg) and xylazine (8 mg/kg) prior to irradiation. Rats were randomly divided into four groups (n=25/group) and three groups were irradiated with 6Gy, 8Gy and 14Gy, on the whole body for 10 to 15 minutes. Irradiation was performed through the use of cobalt60 rays with the device from a Canadian company Tretron, model Phoenix. The cobalt radiation was administered to the body using a 250 kvorthovoltage system. A custom designed positioning device based on the standard steriolactic frame was used so that six animals could be simultaneously irradiated. Dosimetry was performed by implanting lithium fluoride thermoluminescent dosimeters into various areas. The corrected dose rate was determined to be 205/69c GY/min and irradiated with a distance of 7.5 cm on the field of 35x35 in the dorsoventrl axis.

During 30 days after irradiation behavioral changes and other possible clinical symptoms, mainly changes on the body surface and lethality was recorded. The surviving rats at the end of experiment were sacrificed with carbon dioxide, Immediately after irradiation, the rats were freed, placed in their cages, and transferred back to the laboratory where they were allowed to recover from anaesthesia. The animals were monitored till the 30th day post-irradiation, when they were sacrificed. The kidneys, heart, brain, kidney, spleen, lung and liver were carefully dissected out, extracted, rinsed in 10% formalin and then fixed immediately in 10% formalin.

RESULTS AND DISCUSSION

The animals which received the highest dose of irradiation were severely prostrated, very wet with sweat and by the second day some of them were already dead by the 3 day. All the rats in this group died in the 1 week period. Result of quantitative analysis of structural disorders in the central nervous system revealed radiation produced damages early after exposure which correspond to vascular responses and included foci of hemorrhages accompanied with severe vasogenic and cytotoxic edema, on the first week after exposure in group4, rarefaction and necrosis was observed in the subcortical area of brain hemisphere(Fig. 1).The deteriorated regions were surrounded by gliosis, were predominantly located in the white matter of the medullary layer more on the white mater. Hemorrhages were visible either within the necrotic areas or were restricted to areas surrounding the cystic necrosis. In an organ such as the brain, different topographical regions may have varying susceptibility to ionizing radiation. Radiation induced lesions tend to occur more frequently in the cerebral brain white matter. The main findings in this study were the radiation necrosis in the cortex and subcortical area in the brain. There are controversial views as to relative importance of vascular theory versus the glial theory as the prime underlying element of pathogen-nesis of radiation necrosis [7,13].

Histopathological examination of the kidney revealed marked changes in tubules and glomeruli .Early changes noted in the tubules and interstitial tissue. The tubular epithelial cell were swollen with vacuolation with numerous hyaline cast in the lumen (Fig.2). These changes appeared as early as 4th day of post irradiation. There were also severe atrophy and necrosis of the tubules in group three which received the highest dose of radiation.Some tubules showed marked thinning of the epithelial cells which were transformed into a thin layer of cytoplasm covering the basement membrane. The pathophysiology of radiation nephritis is due to cellular injury caused by ionizing radiation [14].Cohen [12] explains that renal injury caused by ionizing radiation is initiated by oxidative injury to deoxyribonucleic acid (DNA), that is, it is a genotoxic injury. It is established that tissue injury elicits acute inflammation whose features among others include swelling of the affected part. This is due to accumulation of exudates particularly fluid, proteins, and cells from local vessels unto the damaged part [15].The hypercellularity in kidneys especially in inflammatory conditions are associated with an increase in cell number linked to cellular proliferation of mesangial, endothelial or parietal epithelium cells.

The animals which received the highest dose of irradiation were severely prostrated, very wet with sweat and by the second day some of them were already dead by the 3rd day. All the rats in this group died in the 1st week period. In all three groups areas of necrotic hepatocytes and cell swelling were seen (figure 3) but in the group 4severe congestion was seen. In all three groups, some of the cells lose their nuclei and cells in tissue can be seen as separate Furthermore, cell swelling occurs and the atmosphere of sinusoid is more expanding. Also pathological study of spleen was showed that necrosis in some parts of the spleen in 3 exposed groups andfibrinoid degeneration in the central splenic vein in group 4(fig4). In the experience in humans that the tolerance of the whole liver is 30–35 Gy in conventional fractionation, but parts of liver can be treated with doses in excess of 70 Gy with three-dimensional radiotherapy treatment planning [16]. Radiation-induced liver disease (RILD), or radiation hepatitis, is a clinical syndrome of anicteric ascites and hepatomegaly occurring 2 weeks to 4 months after hepatic irradiation, because of venoocclusive disease [16].

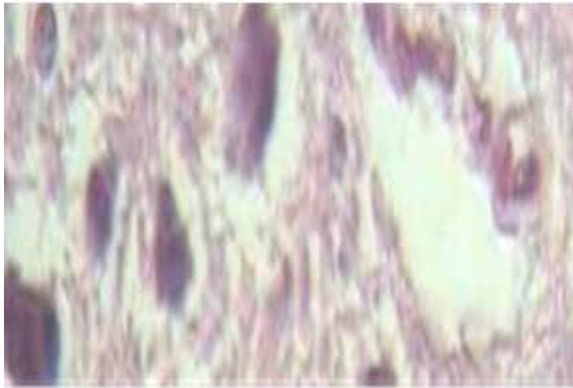

Fig 1. Necrosis in the neurons. The cells have lost their nuclei and normal cell outline. (hematoxylin-eosin; original magnification & 400).

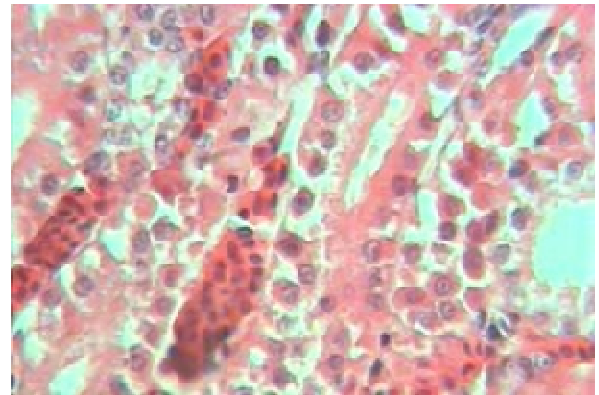


Fig 2. The cytoplasm of the tubular epithelial cells are distended with vacuoles and hyaline casts in the lumen (Hematoxylin-eosin; original magnification x 400)

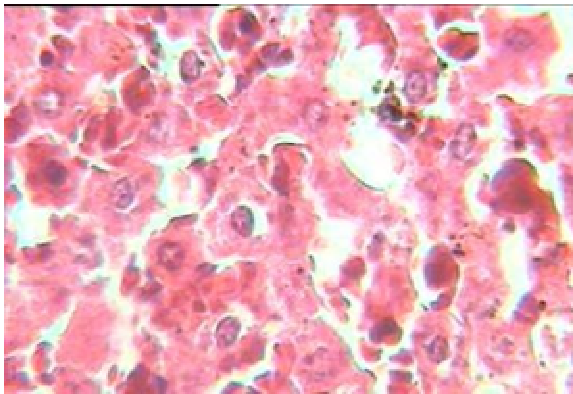


Fig3: Necrosis of liver cells in rat (H&E X400)

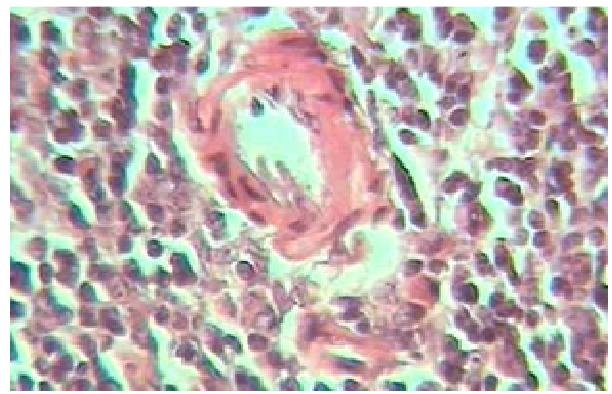


Fig4: fibrinoid degeneration in the central splenic vein in the liver of rat (H&E X400)

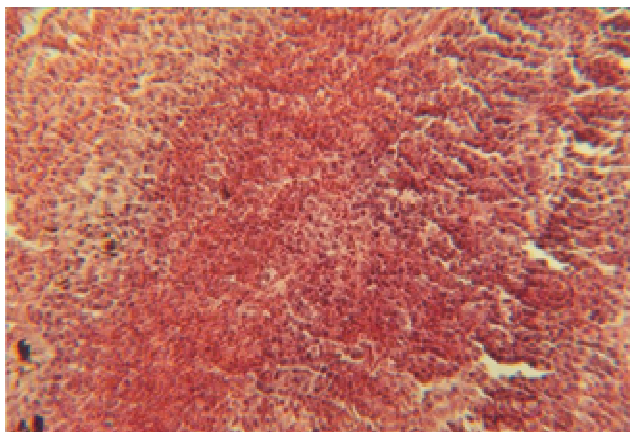


Fig5: hyperemia and necrosis in lung tissue (H&E X400)

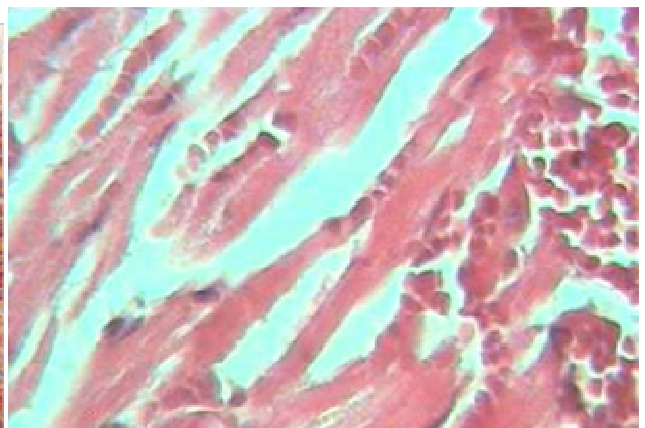


Fig6: blood and edema in the spaces of heart muscular (H&E X400)

The animals which received the highest dose of irradiation were severely prostrated, very wet with sweat and by the second day some of them were already dead by the 3rd day. All the rats in this group died in the 1st week period. Result of quantitative analysis of structural disorders in the lungs revealed radiation produced damages early after exposure which correspond to vascular responses, and edema and hyperemia can be seen in all the 3 groups and goes up as the dosage increases. Also, the thickening of alveolar walls through penetration of unicellular e.g. lymphocytes and macrophages are observed in animals of groups 3 and 4 There are hyperplasia of lymphatic follicles around respiratory tract. Bleeding, wide necrosis in lung tissue and pleural pneumonia could be seen in animals group 4 which received the highest dosage (Fig5). Radiation induced pneumonitis typically develops approximately 6–8 weeks after treatment with doses of 30–40 Gy and is well known early expected effect of therapy that is related to total dose and fractionation [17]. Radiation pneumonitis is most extensive 3–4 months following the end of therapy and eventually becomes radiation fibrosis becomes a stable finding approximately 9–12 months after therapy[18]. Result of quantitative analysis of structural disorders in the muscular strings of heart were narrowed and became of atrophic which led to the gap between heart muscular strings (edema) in groups 2 and 3. While, rupture and necrosis can be seen in group 4. Blood is observed in the spaces of heart muscular strings. A vein in the heart is shown in group 3 which is of degeneracy of fibroids. The wall of hyaline vein becomes monotonous and the cells of endothelium are swollen. (Fig6). Radiation pericarditis generally presents 6–9 months after therapy and the majority of cases occur within 12–18 months of therapy [19]. Both pericardial effusions and pericardial fibrosis are known to occur. Pericardial effusions can be small and incidental findings or large enough to require intervention. Eccentric effusions may occur likely due to adhesions of the treated pericardium[20].

REFERENCES

- [1] Lee AWM, Cheng LOC, Ng SH. **1990** *Clin Radiol* **1990**; 42:24-31
- [2] Rubin, P., D.M. Gash, J.T. Hansen, D.F. Nelson and J.P. Williams, **1994**. *Radiother Oncol.*, 31: 51-60.
- [3] Schultheiss, T.E. and L.C. Stephens, **1992**. *Br J. Radiol.*, 65: 737-753.
- [4] Hindo, W.A., F.A. DeTrana, M.S. Lee and F.R. Hendrickson, **1970**. *Cancer*, 26: 138-141.
- [5] Ljubinova, N.V., M.K. Levitman and E.D. Plotnikova, **1991**. *Br. J. Radiol.*, 64: 934-940
- [6] Panagiotakos, G., G. Alshamy, B. Chan and R. Abram, **2007**. *J. Neurosci. Res.*, 61: 288-294.
- [7] Hopwell, J.W. and A.J. Vander Kogel, **1999**. *Front Radiat Ther Oncol.*, 33: 265-275.
- [8] Kokunai, T., A. Ljichi, S. *Neurol. Med Chir.*(Tokyo), 30: 36-42.
- [9] Kamiryo, T., N.F. Kassell, Q.A. Thai, M.B. Lopes K.S. Lee and L. Steiner, **1996**. *Acta Neurochir.*, 138: 451-459.
- [10] Blatt DR, Friedmann WA, Bova FJ, Theele DP, Mickle JP. **1994**. *J Neurosurg* ; 80:1046-1055.
- [11] Clemente CD, Holst EA. **1954**. *Arch Neurol Psychiatry* ; 71:66-79.
- [12] Cohen E, P. **2002**. *Nephritis, Radiation. Medicine Journal*, 3(3): 1-20
- [13] Schneider, B.F., D.A. Eberhard and L.E. Steiner, **1997**.
- [14] Krochak RJ, Baker DG. **1986**. *Urology*. **1986** 27(5):389-93
- [15] Stevens A, Lowe J. **2000**. *Human Histology*. 2nd ed, London Mosby, pp. 78
- [16] Lepke RA, Libshitz HI. Radiation induced injury of the esophagus. *Radiology* **1973**; 106: 195–7.

- [17] Wallgren A. *Acta Oncol* **1992**; 31: 237–42.
- [18] Libshitz HI. *Semin Roentgenol* **1993**; 28: 303–20.
- [19] Cosset JM, Henry-Amar M, Pellae-Cosset B et al. *Int J Radiat Oncol Biol Phys* **1991**; 21: 447–9.
- [20] Green B, Zornoza J, Ricks JP. *Am J Roentgenol* **1977**; 128: 27–30.